

## TMJ, Principles of Occlusion & Tooth Preparation (Foundational Anatomy)

### I. TEMPOROMANDIBULAR JOINT (TMJ)

#### A. Major Components

- The TMJ is composed of:
  - Cranial base
  - Mandible
  - Muscles of mastication (with innervation and vascular supply)

#### B. Type of Joint

- The TMJ is described as ginglymoarthrodial, meaning it allows:
  - Hinging movement (rotation)
  - Gliding movement (translation)
- Therefore, it is both a hinge and sliding joint.

#### C. Articulating Structures

- 1. Bones Involved
  - Mandibular fossa (temporal bone)
  - Articular tubercle (temporal bone)
  - Condylar process (mandible)
- 2. Articular Surfaces
  - Covered with avascular fibrous tissue
  - Unlike most joints, which are covered with hyaline cartilage

#### D. Articular Disk

- Structure:
  - Made of dense connective tissue
  - Avascular
  - No nerves in normal articulation area
- Attachments:
  - Posteriorly→ Retrodiscal pad (bilaminar zone)

- Medially & laterally → Firmly attached to poles of condyle
- Anteriorly→ Fuses with:
  - Capsule
  - Superior lateral pterygoid muscle

#### E. Retrodiscal Pad (Bilaminar Zone)

- Loose connective tissue
- Highly vascularized
- Highly innervated
- Connects to posterior wall of articular capsule

#### F. Synovial Cavities

- There are two joint spaces:
  - Superior synovial cavity
  - Inferior synovial cavity
- They:
  - Are bordered by capsule and synovial membranes
  - Contain synovial fluid
  - Allow smooth joint movement

#### G. Disk Movement

- Because the disk is firmly attached to condylar poles:
  - It follows condylar movement
  - Moves during both:
    - Rotation (hinge)
    - Translation (glide)
  - Movement is possible due to:
    - Loose posterior connective tissue attachment

### II. LIGAMENTS OF THE TMJ

- The mandible attaches to the skull by:
  - Three Paired Ligaments:
    - Temporomandibular (Lateral) ligament

- Sphenomandibular ligament
- Stylomandibular ligament

#### Functions of Ligaments

- General Rule:
  - Ligaments:
    - Cannot be significantly stretched
    - Limit joint movement
- Specific Functions:
  - 1. Temporomandibular (Lateral) Ligament
    - Limits rotation of mandible
    - Protects joint structures
    - Limits border movements
  - 2. Sphenomandibular Ligament
    - Limits separation between:
      - Condyle
      - Disk
  - 3. Stylomandibular Ligament
    - Limits separation of condyle and disk
    - Limits protrusive movement

### III. MUSCLES RESPONSIBLE FOR MANDIBULAR MOVEMENT

- Grouped into two main categories:
  - A. Muscles of Mastication (Primary muscles for chewing and mandibular movement.)
    - Temporalis
    - Masseter
    - Medial pterygoid
    - Lateral pterygoid
  - B. Suprahyoid Muscles (Assist in mandibular movements)
    - Geniohyoid
    - Mylohyoid
    - Digastric

#### IV. BASIC MOVEMENTS OF THE TMJ

- Because TMJ is ginglymoarthrodial, it performs:
  - 1. Rotation (Hinge Movement)
    - Occurs in inferior joint space
  - 2. Translation (Gliding Movement)
    - Occurs in superior joint space
  - The disk moves together with the condyle during both.

#### V. CONNECTION TO PRINCIPLES OF OCCLUSION

- Understanding TMJ is essential because:
  - Occlusion depends on proper condylar movement
  - Ligaments limit excessive movement
  - Muscles guide mandibular function
  - Disk ensures smooth articulation
  - Synovial fluid reduces friction
- Stable occlusion requires:
  - Proper joint structure
  - Coordinated muscle activity
  - Controlled movement limits

#### VI. CONNECTION TO PRINCIPLES OF TOOTH PREPARATION

- Tooth preparation must consider:
  - 1. Mandibular movements (rotation & translation)
  - 2. Functional pathways of occlusion
  - 3. Joint limitations
  - 4. Muscle forces during mastication
  - 5. Protection of TMJ structures
- Improper occlusal design may:
  - Interfere with translation
  - Strain ligaments
  - Overload muscles
  - Affect disk position

#### MUSCULAR FUNCTION

Mandibular muscle function is:

- Well-coordinated
- Complex
- Involves mastication + suprahyoid groups

#### A. Muscles of Mastication

##### 1. Elevation & Lateral Movement

- Three paired muscles provide:
  - Elevation
  - Lateral movement
- These are:
  - Temporalis
  - Masseter
  - Medial pterygoid

##### 2. Lateral Pterygoid Muscle

- Has two bellies (functionally separate):
  - Inferior Belly
    - Active during:
      - Protrusion
      - Depression
      - Lateral movement
  - Superior Belly
    - Active during
      - Closure
- Also:
  - Attaches to disk and neck of condyle
  - Pulls condyle firmly against disk
  - Helps maintain condyle–disk integrity

#### B. Suprahyoid Muscles

- Have dual function:
  - 1. Elevate hyoid bone
  - 2. Depress mandible
- Function depends on other muscle contraction:
  - If muscles of mastication are contracted:
    - → Suprahyoids elevate hyoid bone
  - If infrahyoid muscles are contracted:
    - → Suprahyoids depress and retract mandible

#### Opening Sequence

1. Geniohyoid & Mylohyoid → Initiate opening
2. Anterior belly of Digastric → Completes depression

#### Stylohyoid Muscle

- Belongs to suprahyoid group
- May indirectly assist
- Not significant in mandibular movement

#### II. DENTITION & OCCLUSION

##### A. Ideal Occlusion

- In ideal cases:
  - Condyles fully seated in mandibular fossae
  - Teeth contact simultaneously
  - No interference with mandibular movement
  - Maximum intercuspation occurs when condyles are seated

##### B. Maximum Intercuspation (MI)

- Defined as:
  - > Complete intercuspation of opposing teeth independent of condylar position

- Also called:
  - Best fit of teeth
- $\triangle$  In many patients:

MI occurs with condyles slightly translated.

### C. Functional Cusps

- In ideal maximum intercuspation:
  - Maxillary lingual cusps
  - Mandibular buccal cusps
- These:
  - Contact opposing fossae
  - Act as vertical stops
  - Prevent excessive loading on one tooth
  - Keep both TMJs unstrained

### D. Angle Class I Relationship

- Exists when:
  - Mesio Buccal cusp of maxillary first molar aligns with buccal groove of mandibular first molar
- Considered:
  - Normal anteroposterior jaw relationship
- Characteristics:
  - Normal molar intercuspation
  - Anterior teeth overlap:
    - Horizontally
    - Vertically
- Malocclusion may still exist:
  - Crowding
  - Rotation
  - Arch length deficiency

### E. Ideal Overlap

- Traditional textbook value:
  - 2 mm horizontal overlap
  - 2 mm vertical overlap

- However:
  - Greater vertical overlap is often better
  - Prevents posterior tooth contact during mandibular flexure
  - Better long-term prognosis

### III. CENTRIC RELATION (CR)

- Defined as:
  - > Maxillomandibular relationship where condyles articulate with the thinnest avascular portion of disks in an anterosuperior position against articular eminence.
- Key Characteristics:
  - Independent of tooth contact
  - Purely rotary movement
  - About transverse horizontal axis
  - Reproducible
  - Reliable reference position

### CR vs Maximum Intercuspation (MI)

- If CR = MI:
  - Restorative treatment is straightforward
- If CR  $\neq$  MI:
  - May require corrective occlusal therapy
  - Must evaluate before restorative treatment

### IV. MANDIBULAR MOVEMENT

- All mandibular movement consists of:
  - 1. Rotation
    - Movement around an axis
    - Pure hinge motion
  - 2. Translation
    - All points move equally
    - Gliding movement

### Movement Can Be Analyzed In Three Planes:

- 1. Sagittal plane
- 2. Horizontal plane
- 3. Frontal plane

### All complex movements are combinations of:

- Rotation
- Translation

### I. REFERENCE PLANES OF MANDIBULAR MOVEMENT

- Mandibular movement can be analyzed in three perpendicular planes:
  - 1. Sagittal
  - 2. Horizontal
  - 3. Frontal
- All movement = Rotation + Translation

### II. SAGITTAL PLANE

- In the sagittal plane, the mandible performs:
  - Pure rotation
  - Translation
  - Combination of both

### A. Rotation (Hinge Movement)

- Occurs around the:
  - Terminal Hinge Axis
  - Imaginary horizontal line
  - Passes through rotational centers of both condyles
- Rotation is limited to:
  - About 12 mm of incisal separation
  - After this  $\rightarrow$  ligaments force translation
- Initial hinge movement:
  - Occurs between condyle and articular disk

## B. Translation

- Occurs when:
  - Lateral pterygoid contracts
  - Condyle–disk assembly moves forward
  - Travels along posterior incline of articular tubercle
- Similar movement occurs during:
  - Protrusion

## III. HORIZONTAL PLANE

- Mandible rotates around vertical axes.

## A. Lateral Movement

- Consists of:
  - 1. Working Side (Laterotrusive) Condyle
    - Rotates around vertical axis
    - Minimal translation
    - May exhibit slight lateral movement called:
      - Laterotrusion
      - Bennett movement
      - Mandibular side shift
    - This may be:
      - Slightly forward → Lateroprotrusion
      - Slightly backward → Lateroretrusion
  - 2. Non-Working (Orbiting / Mediotrusive) Condyle
    - Moves forward
    - Moves medially
    - Limited by:

- Medial wall of mandibular fossa
- Temporomandibular ligament

## B. Straight Protrusive Movement

- Mandible moves anteriorly in a straight path.

## IV. FRONTAL PLANE

- During lateral movement:
  - Mediotrusive (Non-working) Condyle
    - Moves down
    - Moves medially
  - Laterotrusive (Working) Condyle
    - Rotates around sagittal axis

## Transtrusion

- Observed depending on joint anatomy:
  - On mediotrusive side:
    - Controlled by medial wall anatomy
  - On working side:
    - Controlled by lateral wall anatomy
  - Movement may be:
    - Laterosurtrusion (lateral + upward)
    - Laterodetrusion (lateral + downward)

## Straight Protrusion (Frontal View)

- Both condyles:
  - Move downward
  - Slide along tubercular eminences

## V. BORDER MOVEMENTS (Posselt)

- Border movements are:
  - Extreme mandibular movements
- Limited by:

- TMJs
- Ligaments
- Neuromuscular system
- Teeth

- Described by:
  - Posselt
- All mandibular movements occur within these boundaries.

## A. Protrusive Pathway (From MI)

- Starting at Maximum Intercuspatation:
  - 1. Lower incisors guided by lingual concavity of maxillary anterior teeth
  - 2. Posterior teeth gradually lose contact
  - 3. Reach edge-to-edge position
  - 4. Lower incisors move upward
  - 5. Posterior contact reestablishes
  - 6. Further protrusion → little tooth contact

## B. Extreme Borders in Posselt Diagram

- 1. Right Border
  - Most protruded opening & closing stroke
- 2. Lowest Point
  - Maximum opening
- 3. Left Border
  - Most retruded closing stroke
- Two phases:
  - ♦ Lower portion → Rotation + Translation
  - ♦ Upper portion → Pure rotation

## VI. DETERMINANTS OF MANDIBULAR MOVEMENT

- These are anatomical structures that control or limit movement.
- A. Posterior Determinants
  - These are:

- Temporomandibular joints
  - Associated structures
- Include:
  - Shape of articular eminence
  - Medial wall of mandibular fossae
  - Configuration of condyles
- Key Points:
  - Cannot be altered directly
  - Dictate path and timing of condylar movement
  - Steep eminence → greater downward condylar movement
  - Medial wall anatomy → determines side shift
  - Working condyle path → influenced by lateral wall anatomy
  - Side shift does NOT increase due to loss of occlusion
- B. Anterior Determinants
  - These are:
    - Dental articulation
    - Vertical overlap
    - Horizontal overlap
    - Maxillary lingual concavities
  - Unlike posterior determinants:
    - CAN be altered
      - Restorative treatment
      - Orthodontics

#### Effects of Overlap

- Greater Vertical Overlap
  - More vertical early protrusive movement
  - More vertical end of chewing stroke
- Increased Horizontal Overlap
  - More horizontal jaw movement

#### VII. Important Concept

- There is NO proven correlation between:
  - Steep anterior guidance
  - Steep posterior disclusion
- One does NOT necessarily predict the other.

Here is your easy-to-study, high-yield reviewer based ONLY on the information provided. This focuses on important quiz details and removes unnecessary complexity.

#### I. FUNCTIONAL MANDIBULAR MOVEMENTS

- Normal movements during:
  - Mastication
  - Speech
  - Swallowing
  - Yawning
- 🙌 These movements occur within physiologic limits (set by teeth, TMJs, muscles, ligaments)
- ⚠️ Functional movements are not the same as border movements.

#### II. CHEWING (MASTICATION)

- Adult Chewing Pattern
  - 1. Mouth opens comfortably.
  - 2. Mandible moves forward.
  - 3. Anterior teeth meet edge-to-edge to incise.
  - 4. Food moves to center of mouth.
  - 5. Mandible returns to starting position.
  - 6. Slight opening.
  - 7. Mandible moves sideways.
  - 8. Closes into food.
  - 9. Guiding teeth (usually canines) contact.
  - 10. Cycle repeats.
- Important Influences on Chewing
  - Inclination of occlusal plane

- Occlusal guidance near maximum intercuspation
  - Pressoreceptors
  - Feedback from:
    - Tongue
    - Cheeks
    - Periodontium
    - Muscles
  - Children vs Adults
    - Under 10 → Lateral chewing stroke
    - Over 10 → More vertical chewing stroke
  - Mastication is a learned process.
- #### III. SPEAKING (PHONETICS)
- Teeth usually:
    - Do NOT contact during speech
  - Speaking Space
    - Space between maxillary & mandibular teeth during speech.
  - Important sounds:
    - "S", "C", "CH", "Z" → anterior teeth come very close
    - "F" → lower lip touches maxillary incisors
  - 🙌 Phonetics helps evaluate:
    - Vertical dimension
    - Tooth position
    - (Important in prosthodontics)
- #### IV. PARAFUNCTIONAL MOVEMENTS
- Definition: Sustained mandibular activity beyond normal function.
  - Examples:
    - Bruxism
    - Clenching
    - Nail biting

- Pencil chewing
- Effects of Parafunction
  - Excessive tooth wear
  - Widened periodontal ligament
  - Tooth mobility
  - Tooth migration
  - Fractures
  - Muscle pain
  - Headaches
  - Increased radiographic bone density

#### V. BRUXISM

- Definition: Involuntary grinding, gnashing, or clenching outside normal chewing.
- May be:
  - Diurnal
  - Nocturnal (more harmful)
- Prevalence:
  - ~10%
  - Decreases with age
- Causes (Unclear)
  - Possible factors:
    - Malocclusion
    - Emotional stress
    - Neuromuscular disturbance
    - Genetic factors
    - Sleep disturbances
    - Smoking
- Effects of Bruxism
  - Lateral forces on teeth
  - Posterior teeth poorly tolerate lateral forces
  - Rapid PDL widening
  - Tooth mobility
  - Excessive anterior wear
  - Loss of vertical overlap
  - Posterior wear facets develop

- Relationship with TMD: Still unclear

#### VI. CLENCHING

- Definition: Pressing jaws together for prolonged periods.
- Usually related to:
  - Stress
  - Anger
  - Physical effort
  - Concentration
- Differences from Bruxism
  - Force mostly vertical
  - Less lateral damage
  - May not cause tooth damage
- But may cause:
  - Abfractions (cervical defects)
  - Periodontal damage
  - TMJ strain
  - Muscle enlargement
  - Muscle pain

#### VII. PRINCIPLES OF OCCLUSION

##### A. Maximum Intercuspation (MI)

- Most complete tooth contact.
- Often occurs anterior to centric relation.

##### B. Centric Relation (CR)

- Joint-based position.
- Independent of tooth contact.

#### VIII. OCCLUSAL CONCEPTS

##### 1. Bilaterally Balanced Articulation

- Contact:
  - In MI
  - In ALL excursive movements
  - On BOTH sides
- Used in:

- Complete dentures
- Problems in natural dentition:
  - Increased wear
  - Periodontal breakdown
  - Neuromuscular issues
- 2. Unilaterally Balanced Articulation (Group Function)
  - During lateral movement:
    - Contact on working side only
    - No contact on nonworking side
    - No posterior contact in protrusion
  - Advantage:
    - Distributes load across working-side posterior teeth
- 3. Long Centric
  - Allows slight forward movement (0.5–1.5 mm)
  - From CR toward anterior contact.
  - Requires:
    - Horizontal condylar translation
    - Greater horizontal space between anterior teeth
    - Deeper lingual concavity
  - Purpose:
    - Harmonious gliding from CR to anterior contact

#### IX. PRINCIPLES OF TOOTH PREPARATION (From Occlusal Perspective)

- Tooth preparation must:
  - Respect occlusal guidance
  - Maintain functional chewing patterns
  - Avoid interferences
  - Preserve vertical dimension
  - Consider anterior guidance
  - Protect posterior teeth from lateral overload
  - Avoid excessive side shift forces
  - Maintain harmonious CR–MI relationship
- Improper occlusion can lead to:

- Muscle pain
- TMJ strain
- Wear
- Mobility
- Periodontal damage

#### X. BASIC TMJ REVIEW (Functional View)

- TMJ function must allow:
  - Rotation
  - Translation
  - Smooth chewing cycles
  - Controlled lateral movement
  - Stable centric relation
- TMJ, teeth, muscles, and ligaments together:
  - → Control mandibular movement
  - → Limit excessive motion
  - → Protect joint structures

#### MUTUALLY PROTECTED ARTICULATION

- Definition
  - An occlusal scheme where:
    - Centric relation (CR) = Maximum intercuspation (MI)
    - Anterior teeth guide all excursive movements
    - No posterior contacts in lateral or protrusive movements

#### I. KEY PRINCIPLES

##### 1 Anterior Guidance

- 6 maxillary anterior teeth + 6 mandibular anterior teeth
- Guide lateral and protrusive movements
- Prevent posterior contact during excursions
- 👉 Anterior guidance is critical to success.

##### 2 Posterior Teeth Role

- Posterior teeth:
  - Contact only at the end of the chewing stroke
  - Act as vertical stops in MI
  - Should have sharp cusps
  - Cusps pass closely without touching during excursions
- Purpose:
  - Minimize horizontal forces
  - Allow efficient chewing

#### II. FEATURES OF MUTUALLY PROTECTED OCCLUSION

1. Uniform contact of all teeth in MI
2. Stable posterior contacts with vertical forces
3. CR coincides with MI
4. No posterior contact in lateral/protrusive movements
5. Anterior contacts harmonize with jaw movement

#### III. CONDITIONS REQUIRED

- For ideal success:
  - Full set of teeth
  - Healthy supporting tissues
  - No crossbite
  - Angle Class I occlusion

#### IV. WHY ANTERIOR TEETH PROTECT POSTERIOR TEETH

- It may seem illogical to load anterior teeth, but:
  - The mandible is a Class III lever.
  - Class III lever = least efficient lever.
- Meaning:
  - The farther forward the contact (anteriorly),
  - The LESS effective the muscle force,
  - The SMALLER the load on teeth.
- 👉 So anterior teeth reduce force intensity.
- Why Canines Are Important
  - Canines:
    - Long roots
    - Large periodontal surface area

- Strategic position
- Highly sensitive pressoreceptors
- They are ideal for guiding excursive movements.

#### V. ADVANTAGES

- ✓ Minimizes horizontal loading
- ✓ Reduces lateral force on posterior teeth
- ✓ Improves neuromuscular function
- ✓ Enhances chewing efficiency
- ✓ Reduces risk of periodontal breakdown

👉 Posterior teeth in group function receive more horizontal force than in mutually protected articulation.

#### VII. OPTIMUM OCCLUSION PRINCIPLES

- In ideal occlusion:
  1. Load distributed optimally
  2. Forces mostly vertical
  3. Horizontal forces minimized
  4. Functional cusps positioned centrally over roots
  5. Contacts occur in fossae, not marginal ridges
  6. Posterior contact avoided during excursions
  7. Adequate cusp height for efficiency

#### Patient Adaptability to Occlusal Abnormalities:

- Varies widely—some can't tolerate trivial issues; others ignore major malocclusions without symptoms. Most adapt to small deficiencies without acute issues.

#### A. Lowered Threshold:

- Low pain tolerance; poor adaptability to minor occlusal discrepancies.
- Not hypochondria—just heightened sensitivity.

- Easy diagnosis: Patient quickly identifies every pain.
- Varies by situation: Worsens with emotional stress or malaise.
- Symptoms: Severe headaches, muscle spasms, pain.

#### B. Raised Threshold:

- High tolerance; comfortable despite existing malocclusions.
- Signs present (e.g., tooth wear, muscle/TMJ damage) but no pain.
- Treatment still advised: Prevents/minimizes long-term damage to teeth, muscles, TMJs.

#### Pathogenic Occlusion:

- Occlusal relationship causing pathologic changes in stomatognathic system (teeth, periodontium, muscles, TMJs); disharmony between teeth/TMJ leads to symptoms needing intervention.
- **Diagnosis Challenges:** Multiple symptoms overlap; hard to prove direct link to malocclusion, but signs confirm suspicion.

#### A. Teeth Signs:

- Hypermobility: From excessive force (premature contacts in centric/excursive movements); detect by feeling fremitus on tapping.
- Open proximal contacts: Tooth migration from unstable occlusion; check with prior diagnostic casts.
- Abnormal wear: Cusp fracture, chipping, incisal edges; often parafunction + acid erosion (dietary/endogenous like vomiting).

#### B. Periodontium Signs:

- No direct cause of chronic periodontal disease from overload.
- Widened PDL space (radiographic): Indicates premature contact + mobility.
- Isolated/circumferential defects: Linked to occlusal trauma.
- Advanced disease: Minor discrepancies cause rapid migration → hygiene issues → recurrence; precise occlusal adjustment critical (esp. poor crown/root ratio).

#### C. Musculature Signs:

- Pain on palpation: Bruxism/clenching habits.
- Chronic fatigue → spasm/pain (e.g., 30-min grinding causes pain peaking at 2 hrs, lasting 7 days).
- Asymmetric activity: > few mm deviation on opening/closing (frontal plane).
- Trismus: Elevator muscles not relaxing → restricted opening.

#### D. TMJ Signs:

- Pain, clicking/popping: TMD indicators; use stethoscope (reliable).
- Pain may be muscular referral.
- Unilateral reciprocal clicking + midline deviation (toward affected side): Displaced disk blocking condyle translation.

#### Occlusal Treatment Indication:

- Consider when signs/symptoms appear related to occlusal interferences (e.g., pain, wear, mobility, TMD-like complaints).
- **Methods of Occlusal Treatment:**
  - Tooth movement via orthodontics.

- Selective reshaping (selective grinding) to eliminate deflective contacts.
- Restoration or replacement of missing teeth to improve occlusal force distribution.

#### ● Objectives of Occlusal Treatment:

- Direct occlusal forces along the long axis of the teeth.
- Achieve simultaneous contact of all teeth in centric relation.
- Eliminate occlusal contacts on inclined planes to improve positional stability.
- Make centric relation coincide with maximum intercuspation.
- Establish desired occlusal scheme (unilateral balanced vs. mutually protected).

#### ● Short-Term vs. Definitive Treatment:

- Short-term: Removable occlusal device (clear acrylic overlay on one arch).
- Definitive: Selective occlusal reshaping, tooth movement, restorations, or a combination.

#### ● Deprogramming Devices:

- Used to override protective muscular reflexes and accurately manipulate the mandible into centric relation.

#### ● Occlusal Device Therapy (Splints/Appliances):

- Used in TMDs and bruxism; can reduce myofascial pain but mechanism is not fully proven.
- Helps test if a proposed occlusal scheme is well-tolerated ("trial" before fixed restorations).
- Can be maxillary or mandibular; both are satisfactory.

#### ● Direct Device Procedure (Vacuum-Formed Matrix):

- Vacuum-form clear thermoplastic matrix on diagnostic cast; trim away from gingival margins.
- Try in, add autopolymerizing resin on incisor/canine area; guide mandible into centric relation (bimanual technique) and mark contacts.
- Build up incisor/canine contacts first, then posterior contacts, and adjust excursions to achieve incisal guidance and dog-tooth guidance.
- Relieve posterior contacts for posterior disclusion; refine with marking ribbon and occlusal adjustment.
- **Indirect Device Procedure (Autopolymerizing Resin):**
  - Require accurately mounted diagnostic casts at correct occlusal vertical dimension and centric relation record.
  - Use articulator with incisal guidance table; set 1 mm clearance in posterior teeth, then in protrusive and lateral excursions.
  - Block out undercuts, make clasps, seal casts, and build device with autopolymerizing resin on the cast.
  - Refine occlusion on articulator: even functional cusp contacts in centric, anterior stops, smooth protrusive and lateral contacts (laterotrusive canines).
- **Indirect Alternative (Heat-Polymerized Resin):**
  - More durable; desired occlusal surface is waxed on mounted casts, then flanked and processed like a denture.
  - Remount and adjust after processing to correct small errors.
- **Attention to Detail:**

- Critical in both direct and indirect methods (e.g., accurate centric relation record, stable matrix, proper anterior guidance before adding posterior resin).
- Inaccurate mounting is a common cause of excessive adjustments at delivery.
- **Follow-Up After Delivery:**
  - Verify and refine occlusion; patient wears device 24 hours/day (removes only for hygiene).
  - Weekly/biweekly visits; if discomfort decreases, definitive occlusal adjustment or restorative treatment is likely to succeed.
  - If symptoms persist, re-evaluate etiology (e.g., non-occlusal factors).
- **Summary Concepts:**
  - Balanced occlusion: Stable in edentulous patients; potentially harmful in dentate patients.
  - Group function (unilateral balanced): Lateral contacts on laterotrusive posteriors; distributes load.
  - Mutually protected articulation: Centric relation = maximum intercuspation; anterior guidance protects posteriors; most ideal for dentate patients.
  - Occlusal therapy should be completed before major restorative or fixed prosthodontic work.

#### Important Points

- Occlusal contact affects muscle activity.
- Poor restorative work can disturb muscle timing.
- Stabilizing contacts mainly involve mandibular buccal cusps.
- Maintaining these contacts is a treatment objective.

---

#### VIII. HIGH-YIELD QUIZ RECALL

- ✓ CR must equal MI
- ✓ Anterior teeth guide excursions
- ✓ No posterior contact during excursions
- ✓ Posterior teeth act as vertical stops
- ✓ Mandible = Class III lever
- ✓ More anterior contact = less force
- ✓ Canines best for guidance
- ✓ Posterior teeth should not receive lateral forces
- ✓ Forces should be parallel to long axis of teeth
- ✓ Functional movements ≠ border movements
- ✓ Chewing guided by canines
- ✓ Children chew laterally
- ✓ Speaking space = teeth slightly apart
- ✓ Bruxism = grinding (often nocturnal)
- ✓ Clenching = sustained vertical pressure
- ✓ Posterior teeth poorly tolerate lateral forces
- ✓ Bilateral balance = both sides contact
- ✓ Group function = working side only
- ✓ Long centric = 0.5–1.5 mm freedom
- ✓ MI often anterior to CR
- ✓ Terminal hinge axis = rotation center
- ✓ Rotation limited to ~12 mm before translation
- ✓ Translation = lateral pterygoid contraction

- ✓ Working condyle rotates
- ✓ Non-working condyle moves forward & medially
- ✓ Bennett movement = side shift
- ✓ Posselt diagram = border movements
- ✓ Posterior determinants = TMJ anatomy (not alterable)
- ✓ Anterior determinants = teeth (alterable)
- ✓ Greater vertical overlap = more vertical jaw movement
- ✓ No correlation between anterior & posterior steepness
- ✓ 3 elevating muscles → Temporalis, Masseter, Medial pterygoid
- ✓ Lateral pterygoid inferior belly → Protrusion & depression
- ✓ Lateral pterygoid superior belly → Closure & disk stabilization
- ✓ Suprahyoids depress mandible only if infrahyoids contract
- ✓ MI = best fit of teeth, independent of condyle
- ✓ CR = independent of teeth, purely rotary
- ✓ Functional cusps = Maxillary lingual + Mandibular buccal
- ✓ Angle Class I = MB cusp of maxillary 1st molar aligns with buccal groove of mandibular 1st molar
- ✓ Ideal greater vertical overlap = better prognosis
- ✓ Mandibular movement = Rotation + Translation
- ✓ TMJ type → Ginglymoarthrodial
- ✓ Disk → Avascular, dense connective tissue
- ✓ Retrodiscal pad → Vascular & innervated
- ✓ Two joint spaces → Superior & Inferior synovial cavities
- ✓ Ligaments limit movement
- ✓ Stylomandibular ligament limits protrusion
- ✓ Disk follows condyle during movement
- ✓ Muscles of mastication = 4
- ✓ Suprahyoid muscles = 3

## Chapter7

- Teeth cannot regenerate enamel or dentin once lost from caries, trauma, or wear; restorations are needed to restore form and function.
- Tooth preparation must follow basic principles to predict success of prosthodontic treatment; careful attention to detail is essential.
- Three main categories of tooth-preparation principles:
  - Biologic: Health of pulp, periodontium, and soft tissues.
  - Mechanical: Retention, resistance, durability of the restoration.
  - Esthetic: Appearance of the restoration and tooth.
  - Always balance all three considerations; improving one (e.g., esthetics with more porcelain) can harm another (e.g., pulp health, tooth strength).

## Biologic Considerations – Prevention of Damage

- **Adjacent teeth:**
  - Iatrogenic damage to proximal enamel is common and increases caries risk (less fluoride, more plaque retention).
  - Protect by using the proximal enamel of the prepared tooth itself; a thin tapered diamond through the contact area can leave a small enamel fin, avoiding excessive reduction and instrument angulation errors.
  - Metal matrix bands may help but can still be perforated and damage enamel.
- **Soft tissues:**
  - Protect tongue and cheeks with retraction (aspirator, mirror, flanged ejector), especially on lingual surfaces of mandibular molars.
- **Pulp:**
  - Avoid irreversible pulpitis from heat, chemicals, or bacteria, especially on freshly cut dentin.
  - Evaluate pulp size on radiographs; it decreases with age, more occlusocervically than faciolingually.

## Causes of Pulp Injury

- **Temperature:**
  - High heat from friction (bur, poor technique) causes damage.
  - Use a light touch, high-speed handpiece, and a properly directed water spray to cool, clean debris, and prevent dentin desiccation.
  - For grooves or pinholes, use low speed because coolant cannot reach the cutting edge.
- **Chemical action:**
  - Bases, resins, solvents, and luting agents on freshly cut dentin can irritate the pulp.
  - Cavity varnish or dentin bonding agents can act as a barrier, but their effect on cement retention is debated.
  - Chemical cleaning/degreasing agents are pulpal irritants and generally contraindicated.
- **Bacterial action:**
  - Microleakage or remaining carious dentin can lead to pulpal infection under restorations.
  - Vital dentin resists infection; antibacterial cements (e.g., zinc phosphate) help, but routine antimicrobial use is not strongly supported by evidence.
  - All carious dentin must be removed before foundations for fixed prostheses; indirect pulp capping is not recommended on teeth destined for cast restorations.

## Conservation of Tooth Structure

- **Fundamental tenet:** Remove as little tooth structure as possible while still meeting mechanical and esthetic requirements.
- **Thicker remaining dentin = less pulpal response;** preparations close to the pulp should be minimized.
- **Guidelines to conserve tooth structure:**
  - Prefer partial-coverage over full-coverage restorations when possible.
  - Use minimal practical taper (convergence) between axial walls.
  - Reduce occlusal surface following anatomic planes for uniform restoration thickness.
  - Preserve maximum residual tooth structure around the pulp; reposition teeth orthodontically if needed to reduce axial taper.
  - Use conservative, but functional, margin geometry (e.g., chamfer, shoulder).
  - Avoid unnecessary apical extension of the preparation.

## Considerations Affecting Future Dental Health

- **Poor preparation** → **periodontal disease or caries** if margins are overcontoured, hard to clean, or placed in stressful areas.
- **Axial reduction & gingival health:**
  - Overcontoured crowns and bridges correlate with gingival inflammation because plaque control is more difficult.
  - Preparations must allow smooth, anatomic contours without ledges; if in doubt, slightly undercontoured crowns are easier to keep clean.
  - In some cases, slightly increased proximal contour on anterior crowns helps maintain interdental papilla.
  - Sufficient axial reduction is especially important in interproximal and furcation areas of posterior teeth to prevent periodontal disease.
- **Occlusal reduction and margin location:**
  - Insufficient occlusal reduction → poor form, occlusal dysfunction.
  - Poorly placed margins (e.g., in occlusal contact areas) → enamel chipping or cusp fracture.
- **Margin placement priority:** Whenever possible, place the margin **supragingival**; subgingival margins are a major risk factor for periodontal disease, especially if they invade the epithelial attachment.
- **Supragingival margin advantages:**
  - Easier to prepare accurately without soft-tissue trauma.
  - Usually placed on enamel (more resistant than dentin/cementum).
  - Easier to keep plaque-free.
  - Impressions are easier and safer.

- Easier to evaluate at placement and follow-up.
- **When subgingival margin is justified:**
  - Caries, cervical erosion, or existing restorations extend subgingivally and crown-lengthening is not indicated.
  - Proximal contact area extends to gingival crest.
  - Additional retention/resistance needed.
  - Metal-ceramic margin needs to be hidden behind labiogingival crest.
  - Root sensitivity uncontrolled by conservative measures (e.g., bonding agent).
  - Axial contour modification needed (e.g., undercut for RPD clasp).
- **Margin adaptation:**
  - Tight margin adaptation reduces risk of recurrent caries and periodontal disease.
  - Well-designed preparations have smooth, even margins; “stepped” or rough margins increase overall length and decrease adaptation.
  - Skilled technicians can achieve ~10 μm fit for castings and ~50 μm for porcelain margins if the tooth is well-prepared.
- **Margin geometry guidelines:**
  - Must be easy to prepare, visible in impression/die, distinct for wax finishing, provide adequate material bulk, and conserve tooth structure if possible.
- **Unacceptable margins:**
  - Feather-edge (no bulk, leads to overcontoured restorations).
  - Chisel-edge (often associated with excessive taper and poor axial alignment).
  - Used mainly with outdated rigid impression techniques; not ideal today.
  -

- **Chamfer margin:**
  - Suitable for **cast metal crowns** and metal-only parts of metal-ceramic crowns.
  - Distinct, easy to see, provides enough bulk for proper contours.
  - Best prepared with a **tapered diamond with rounded tip**; no wider than half the tip diameter to avoid unsupported enamel.
  - Must follow intended path of seating; tilting creates undercuts or over-reduction.
- **Beveled margin:**
  - Useful when a ledge or shoulder already exists (caries, erosion, previous restoration).
  - Goals: allow burnishing, minimize marginal discrepancy, remove unsupported enamel.
  - Limited advantage if access is tight (e.g., gingival margin, where it may push preparation subgingival or onto dentin).
  - Recommended on **facial margins of maxillary partial-coverage restorations** to prevent fracture and allow burnishing.
- **Shoulder margins:**
  - Provide space for porcelain; recommended for **facial margin of metal-ceramic crowns**, especially with porcelain-to-gingiva margin technique.
  - Ideally at **90° angle** to unprepared tooth; acute angles prone to chipping.
  - Clinicians often underprepare facial shoulders, leading to poor esthetics or contour.
- **Heavy chamfer vs. shoulder:**
  - Some prefer a heavy chamfer for facial metal-ceramic margins for ease and reduced framework distortion.

- Modern alloys show similar results for shoulder and heavy chamfer.
- **Sloped shoulder (120°):**
  - Alternative to 90° shoulder for metal-ceramic crowns; reduces risk of unsupported enamel and allows thinning metal to knife-edge for esthetics.
- **Beveled shoulder:**
  - Sometimes used when a **metal collar** (no porcelain labial margin) is planned; removes unsupported enamel and allows metal finishing.
  - Shoulder or sloped shoulder is generally preferred for better biologic and esthetic outcomes.
- **Occlusal considerations:**
  - Prep must allow enough space for functional occlusion.
  - Supraerupted or tilted teeth may need substantial reduction; this can shorten axial walls (less retention/resistance) and may even require endodontic treatment.
  - Diagnostic tooth preparations and wax-ups help determine exact reduction needed.
- **Preventing tooth fracture:**
  - Intracoronary inlays tend to separate opposing walls under load; thin remaining walls increase fracture risk.
  - Cuspal coverage (onlay) reduces fracture risk compared with inlay.
  - Full-coverage crowns provide the best protection by “holding” cusps together, especially in weakened or endodontically treated teeth.

## Mechanical considerations

- in fixed prosthodontics: design must prevent dislodgement, distortion, and fracture of the restoration.
- Divided into **(1) retention form**, **(2) resistance form**, and **(3) prevention of restoration deformation**.

### Retention form

- Refers to the ability of the prep to resist dislodging forces acting **parallel to the path of placement** (e.g., sticky food, floss-pulling).
- Lack of retention is a major cause of crown and FPD failure (after caries and porcelain fracture).

### Factors affecting retention:

1. **Magnitude of dislodging forces**
  - Forces from very sticky food (e.g., caramel) are usually greater than those from normal function.
  - Depends on food stickiness, occlusal surface area, and restoration texture.
2. **Geometry of the tooth preparation**
  - Traditional cements are non-adhesive; they mainly increase friction.
  - The tooth prep must give the restoration a **single, limited path of placement** (like a nut on a bolt).
  - If one wall is overtapered, the crown gains **multiple paths of withdrawal** → greatly reduced retention.
3. **Taper (convergence angle)**
  - **Theoretical maximum retention:** completely parallel walls—but this creates undercuts and makes seating impossible.
  - **Undercut:** any area where the cervical margin is narrower than the occlusal-axial junction (reverse taper).

- **Optimal clinical taper:** about **6° convergence between opposing axial walls.**
    - More than 6° → rapid loss of retention.
    - Much less than 6° → risk of undercuts and over-preparation.
  - Use a **rotary instrument of the desired taper** held at constant angulation; avoid deliberately tilting the bur.
  - Clinicians often overtaper more in **buccolingual** than mesiodistal direction; FPD abutments tend to be more tapered than single-crown preps.
4. **Surface area (length of axial walls)**
- Longer axial walls → more surface in sliding contact → more retention.
  - Molar crowns are more retentive than premolar crowns of similar taper (larger diameter).
  - Occlusal surface contact does not significantly increase retention.
5. **Grooves, boxes, pins**
- If the preparation already has a limited path of placement, **adding grooves/boxes only slightly increases retention** (surface area increase is small).
  - However, if a groove **limits additional paths of placement**, it significantly improves retention.
6. **Stress concentration**
- Retentive failure often happens as **cohesive failure within the cement**, not at the tooth–cement or cement–restoration interface.
  - Stresses concentrate at the **occlusoaxial line angle** → round sharp angles to reduce stress and prevent premature failure.
7. **Type of preparation**

- **Complete crown** has much higher retention than **partial-coverage** (double or more) when height and taper are similar.
  - Other features (offsets, grooves, boxes, shoulder, isthmus, proximal box) enhance retention and resistance.
8. **Roughness of the fitting surface**
- Very smooth internal surface → failure at **cement–restoration interface**; roughening improves retention.
  - Best roughening methods: **air-abrasion with 25–50 μm alumina** or **acid-etching** (for some resin cements).
  - **Do not roughen the tooth prep**; this does not improve retention but complicates impression-making and waxing.
9. **Materials being cemented**
- **Base metal alloys** generally show better retention than high-gold-content alloys when using traditional cements.
  - Core material matters: amalgam may adhere better to cement in lab tests, but some studies show **composite cores give higher overall retention** than amalgam cores (possibly due to dimensional stability).
10. **Type of luting agent**
- **Adhesive resin cements** are the most retentive in vitro.
  - However, long-term durability of the resin-dentin bond is uncertain (risk of **nanoleakage** and hybrid-layer breakdown).
  - Acid-resistant, thin-film cements (e.g., glass ionomer, resin cements) generally improve retention.
11. **Film thickness of the luting agent**

- Effect of thicker cement film on retention is controversial.
- Very thick film can reduce retention; very thin film (e.g., when using die-spacer) may increase it, but long-term clinical data are limited.

#### Resistance form

- features that prevent **dislodgment of a cemented restoration by tipping/rotation**, especially under **horizontal/oblique forces** (e.g., parafunction, eccentric occlusion).
- Forces tend to rotate the crown around the **gingival margin**; **resistance areas** are tooth-prep surfaces that compress the cement and block this rotation.

#### Key factors affecting resistance form

1. **Magnitude and direction of dislodging forces**
  - Patients can generate huge biting forces (e.g., > 4000 N in extreme cases).
  - Posterior restorations loaded in eccentric contact experience especially large oblique forces.
  - From a durability standpoint, adequate resistance form may be **more critical than overall retention**.

#### Geometry of the tooth preparation

- Resistance depends on **taper, preparation height, and diameter.**
  - Increased taper or diameter → less resistance.
  - Shorter prep height → less resistance.
- **Clinically acceptable taper range:** about **5–22° combined**; near the upper end, resistance drops sharply.

- **3 mm height** gives adequate resistance if taper  $\leq 10^\circ$ , but **molars often need 3.5–4 mm** height and more parallel walls.
- **Pyramidal (more parallel) preps** → **more resistance** than conical (overtapered) preps
- **Grooves, boxes, and pins**
  - **Proximal grooves/boxes** greatly enhance resistance by blocking rotational movement and putting more cement into compression.
  - **U-shaped or flared grooves/boxes** resist more than V-shaped ones.
  - In excessively tapered walls, grooves should be **deeper cervically** than occlusally to improve resistance.
  - **Cervical taper restriction** in an overtapered prep is more effective than relying only on grooves.
  - Pinholes can be used as an alternative to grooves/boxes.
- **Type of restoration**
  - **Partial-coverage restorations** generally have **less resistance** than complete crowns because they lack buccal resistance areas.
  - Resistance in partial-coverage is mainly from **grooves/boxes** designed perpendicular to the expected force direction.
- **Physical properties of the luting agent**
  - Higher **compressive strength** and **modulus of elasticity** (less plastic deformation) → better resistance to displacement.
  - **Zinc phosphate cement** has high compressive strength (> 70 MPa at 24 h) and high modulus; performs well in resistance tests.

- **Glass-ionomer and resin cements** have higher compressive strength than zinc phosphate; **polycarboxylate** is similar.
- **Zinc-oxide–eugenol–type cements** weaken dramatically with temperature rise (e.g., from 23°C to 37°C or 50°C), reducing resistance.
- **Preventing deformation** = ensure the restoration is strong enough to resist **permanent bending or fracture** under function; failure usually occurs at the **restoration–cement** or **metal–porcelain** interface.
  - **Alloy selection**
    - **Type I/II gold alloys** are too soft for crowns/FPDs; **type III/IV gold or low-gold alternatives** are used instead (harder, can be hardened by heat treatment).
    - **High-noble metal-ceramic alloys** are about as hard as type IV gold; **nickel-chromium alloys** are harder and useful for long-span FPDs but carry biologic and casting challenges.
- **Adequate tooth reduction**
  - Even strong alloys need **sufficient bulk** to resist occlusal forces.
  - **Minimum alloy thickness:**
    - **1.5 mm** over functional cusps (mandibular buccal, maxillary lingual).
    - **1 mm** over non-functional cusps.
- Occlusal reduction should be **uniform**, following cuspal planes; this preserves tooth structure while giving adequate clearance and allows an **anatomically “corrugated”** (rigid) occlusal form.
- Supraerupted or malaligned teeth may need **more than 1.5 mm reduction**; diagnostic prep and wax-ups help determine correct reduction.

### Margin design and distortion prevention

- Avoid **occlusal contact on the margin**; keep margins about **1–1.5 mm** away from functional contact areas.
- Provide **enough metal bulk at the margin** (e.g., chamfer instead of feather-edge) to prevent bending.
- On **increased-taper preparations**, accept **narrower margins** to protect pulp thickness (balance biologic vs mechanical).
- **Grooves and ledges** in partial-coverage restorations (especially pin-ledge retainers) add “beam-like” reinforcement and reduce casting distortion.

### Esthetic considerations – core ideas

- Esthetics should not override **biologic health** or **function**; discuss expectations, visibility during speech/smiling, and hygiene with the patient.
- Main options: **partial-coverage crowns**, **metal-ceramic**, and **all-ceramic** restorations.

### All-ceramic restorations

- Excellent esthetics, can mimic natural tooth color well; higher risk of **brittle fracture**, but newer materials and **resin-bonded luting** improve strength.
- Require **wide 90° heavy chamfer margins** and extra lingual reduction for adequate **1–1.2 mm** minimum thickness.
- Often unsuitable for **thin-walled teeth** or **large-pulp young teeth** because of required tooth reduction.

### Metal-ceramic restorations

- Compromised appearance is often due to **insufficient porcelain thickness**; too much porcelain can lead to **overcontoured crowns** and periodontal disease.

- **Facial reduction:** usually  $\geq 1.5$  mm to provide enough porcelain for color depth and translucency.
- **Shade matching:** opaque porcelain at incisal/cervical thirds can create noticeable “hot spots”; use special stains to blend.
- With **very thin teeth (e.g., mandibular incisors)**, may have to accept suboptimal looks to avoid pulp exposure or weak preparations.

#### Facial, incisal, and proximal design

- **Facial surfaces** (anterior MCR) should be reduced in **two planes** (cervical + incisal), not one continuous plane, so neither area is under-reduced.
- **Incisal edge: 2 mm reduction** recommended for esthetic translucency; avoid excessive reduction to preserve retention/resistance.
- **Proximal areas:**
  - For natural-looking anterior partial-coverage, restore **only incisal-edge-proximal areas without metal** so light can transmit.
  - In FPDs, connectors usually require more metal, limiting this effect.

#### Labial margin placement

- **Supragingival margins** are better for biologic health and cleanliness.
- **Subgingival margins** may be used for esthetics (high lip line) or to hide metal; metal-collar margins can be placed supragingivally if not visible.
- Metal margins generally fit **more accurately** than porcelain margins, but some patients dislike exposed metal.
- If hiding metal in the sulcus:

- Treat **healthy periodontium first**; avoid encroaching on epithelial attachment.
- Allow **~2 mm sulcus depth** after surgery; wait until tissue stabilizes (~20 weeks).
- Margins should follow **free-gingival contour** (more apical mid-facially, more incisal interproximally); avoid straight-plane preparations that expose labial metal and cause loss of bone/papilla.

#### Partial-coverage restorations

- Preferred when esthetically acceptable, because they **conserve enamel** and look more natural than any restorative material.
- **Proximal margins:**
  - Place **just buccal to the contact area** so metal is hidden by the neighbor’s distal line angle but still accessible for hygiene.
  - Margins too far facial/lingual increase risk of visible metal; axial angulation must follow tooth long axis.
- **Facial margins** (maxillary partials):
  - Extend **just beyond the occluso-facial line angle**; short bevel to prevent chipping.
  - Use **chamfer** where strength is critical (e.g., molars).
- **Buccal margins** should **follow original cuspal contour** so they do not reflect light; if well-shaped, the tooth looks slightly shorter, not “metal-rimmed.”
- **Mandibular partials:** metal display is often unavoidable; use **chamfer** on buccal margin for strength; if metal is unacceptable, switch to **metal-ceramic** with porcelain occlusal coverage.

- **Anterior partials with no metal** are possible (Fig. 7-55) but require careful prep; facial margin extends **just beyond the incisal-edge high contour but not to the incisolabial line angle**, so metal is hidden but still protective.
- **Tooth preparation** is technically complex and **irreversible**; mistakes are hard or impossible to correct, so every step must be done carefully.
- **Diagnostic tooth preparations (on casts):**
  - Perform on **articulated diagnostic casts** before clinical prep.
  - Help choose the **best path of placement** for FPDs, especially with **tilted or atypical crowns**.
  - Determine **how much tooth reduction** is needed for planned occlusal changes.
  - Decide on **facial and proximal margin placement** for partial-coverage crowns to **hide metal**.
  - Allow the operator to **practice each step** without permanent damage and to **prefabricate interim restorations**, saving chairside time.
- **Diagnostic waxing procedures:**
  - Do **diagnostic wax-ups** on diagnostic preps for all but very simple cases.
  - Establish **optimum contour and occlusion** of the final prosthesis.
  - Especially useful when the **occlusal scheme** or **anterior incisal guidance** needs to be changed.
- **Evaluative steps during clinical preparation:**
  - Evaluate **each step** with **direct vision** and **dental mirror**.
  - Use mirror to **superimpose images** of multiple abutments when checking alignment.
  - Take an **alginate impression** of complex preparations and pour in **fast-setting stone**; use

a **dental surveyor** to measure **axial inclinations** and check for undercuts or excessive taper.

- Learn to use the **contra-angle handpiece as a measuring tool**:
  - Keep the **top of the head perpendicular to the tooth's occlusal surface** (parallel to occlusal plane).
  - Maintain this **constant angulation** during axial reduction to avoid undercuts or excessive convergence.
  - The **diamond instrument's taper** sets the wall taper; do not tilt the handpiece.
  - Support the handpiece with the **opposite-hand finger** for better control.

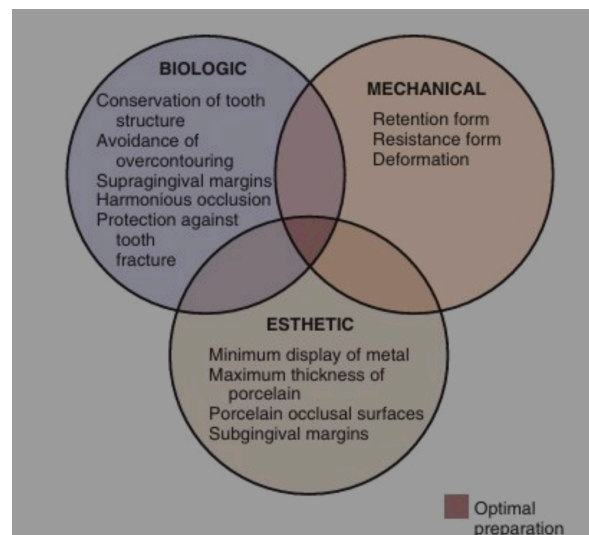
- **Patient and operator positioning:**

- Proper positioning is **as important as the technique itself**.
- Always prefer a **direct view** of the preparation over a mirror view when possible.
- For invisible areas (e.g., distal surfaces of maxillary molars), **adjust the patient's head position** (turn left/right) to improve access and view.
- A **maximally open mouth** is not always best; a **partially open mouth** often allows better **cheek retraction** and better view of the **distobuccal line angle** and **buccal third of the distal wall**.
- Use the **mirror mainly for small distal areas**; most of the tooth can be seen directly with proper positioning.
- When doing a **complete crown**, prepare the **most visible areas first**, then use the mirror to finish the **harder-to-see regions**.

## PRINCIPLES OF TOOTH PREPARATION

- Teeth do not possess the regenerative ability found in most other tissues.
  - Once you have lost, specially you permanent tooth or teeth, it will not grow back

- Teeth require preparation to receive restorations.
  - Cavity preparation for resto and for FPD you have tooth reduction which has significant reductions.
- Careful attention to every detail is imperative during tooth preparation.
- A good preparation will ensure that subsequent techniques can be accomplished properly.
  - The success or failure of restorations, specially in FPD, depends on multiple factors.
- Factors:
  - Biological
  - Mechanical
  - Esthetics



- Goal as a clinician to fabricate an optimal restoration by complying or by considering 3 factors.
- Optimum restoration should satisfy all biologic, mechanical and esthetic requirements.

#### Biological Considerations

- Affects the health of oral tissue

#### A. Prevention of damage during tooth preparation

- Adjacent
- Soft tissues (gingiva, tongue)
- Pulp
- Iatrogenic damage: operator induce injury

##### 1. Adjacent

- Metal matrix band around the adjacent tooth
  - Even if you only touched the surface or nare-countour lang ng kunti ung surface, the outer enamel layer is already damaged. In the tooth, the outer enamel layer is fluoride ditched. May content na flouride. So kapag nagasgasan na siya, mawawala na yung outer enamel layer na yun. The surface now will also become rough. When the surface is rough, it is prone to plaque retention. Kahit minimal lang yung injury, kapag nawala na yung surface enamel, malaki na yung damage sa adjacent teeth. If it is more prone to plaque retention, higher susceptibility to caries.
  - Also compromise the proximal contact of restoration in terms of long term. As mentioned, the original enamel surface is biologically superior to a repolished surface. Kahit among polish or pakinis, basta nagasgasan na yung enamel, you cannot restore as it is because hindi nagreregenerate ang ngipin.
  - This is why adjacent tooth damage is not a minor error but it is a gross error because it can create a form of your anterior guidance only in canine guidance
  - Group function

- Also known as unilateral balance occlusion. This is an occlusal scheme in which during lateral movement or working side movement multiple posterior teeth would contact simultaneously actually posterior kasi sometimes or most of the time also the canine and the premolars would be in contact. All contacts would occur on the working side only while the nonworking side would remain free of contact. So during lateral movement several posterior teeth contact together on the working side. This contact would actually guide the mandible and it would share occlusal load. So unlike in canine guidance na si canine lang ang nagcocontact, sa group function, the forces will not be concentrated on one tooth instead it will be distributed across a group.
- When do you actually use group functions?
  - This is only an alternative to canine guidance. Sometimes it's not all the time that there will be a canine present especially if you are dealing with prosthodontic cases already.

Impact on Selected Variables on Occlusal Form of Restoration		
Anterior Determinants	Variables	Impact on Restoration
Horizontal overlap of anterior teeth (overjet)	Increased Effect? <ul style="list-style-type: none"> <li>Less effective anterior guidance</li> <li>Posterior teeth are less disoccluded during excursion</li> </ul>	Cusp must be shorter <ul style="list-style-type: none"> <li>To avoid posterior interference during movement.</li> </ul>
	Reduced Effect? <ul style="list-style-type: none"> <li>Have a very strong anterior guidance but you will also have a better posterior disocclusion</li> </ul>	Cusp maybe taller <ul style="list-style-type: none"> <li>Because the posterior teeth are actually separated more during movement</li> </ul>
Vertical overlap of anterior teeth (overbite)	Increased (deep bite) <ul style="list-style-type: none"> <li>You have greater vertical coverage of the mandibular incisor.</li> </ul>	Cusp maybe taller <ul style="list-style-type: none"> <li>Posterior teeth would be separated quickly during excursions.</li> </ul>

<ul style="list-style-type: none"> <li>Effect: steeper anterior guidance, rapid posterior disocclusion</li> </ul>	
Reduced (open bite/ shallow) <ul style="list-style-type: none"> <li>Would result in a very minimal vertical overlap.</li> <li>Effect: flatter anterior guidance and less posterior disocclusion.</li> </ul>	Cusps must be shorter <ul style="list-style-type: none"> <li>No interferences</li> </ul>

- In other words, anterior guidance determines the posterior height. If you have a very steep guidance or deep overbite, it would allow you to have a taller cast for the restoration. But if you have shallow guidance, if you have an open bite or large overjet, it would require a shorter cast from the restoration. So when fabricating the crowns of fixed bridges, you must evaluate the overjet and the overbite of the patient.
- Failure to follow this relationship can actually lead to occlusal interferences.

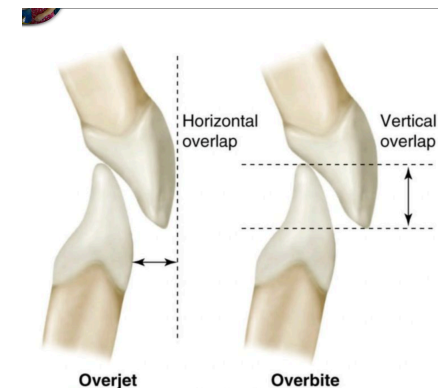


FIG. 16.16 The terms *overjet* and *overbite* are commonly used to describe horizontal and vertical overlap of teeth.

- Horizontal overlap is overjet. This is the horizontal distance between the upper and lower front teeth. This is actually how far upper teeth would stick forward. It protruded.
- Vertical overlap of the upper front teeth over the lower front teeth, this is the overbite. This is how much the maxillary teeth would cover the lower teeth vertically.
- Overbite is the forward gap and overbite is the vertical cover.

## 2. Periodontal structures

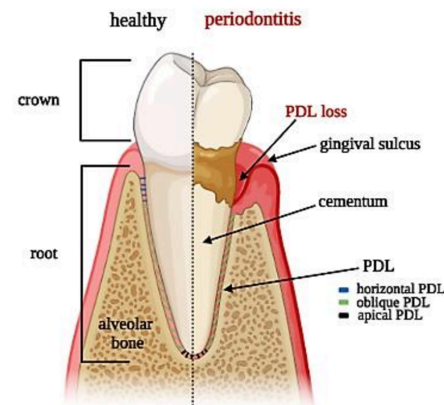
- These structures collectively support the tooth and it helps function under occlusal forces.
- Overall role in occlusion is:
  - Shock absorbent or shock absorption
  - Proprioception or sensory feedback
    - The PFL actually contains the mechanoreceptors which detect the bite force, the tooth contact and the position. When the PDL would detect this then it actually helps in fine control of your chewing and it also protects the tooth from excessive forces
- Components:
  - Periodontal ligament (PDL)

- Since it is an elastic structure wherein when force is applied it compresses and distributes the stresses to the alveolar bone that is why you have several types of periodontal ligament so this prevents direct trauma to the bone. It also prevents tooth fracture under normal function
- What is the role of PDL in static occlusion?
  - When you say static occlusion it is the tooth in contact with the tooth in maximum intercuspation.
  - it maintains tooth stability under vertical forces (How the forces are directed along the long axis of the tooth). Therefore, the Periodontal fibers would resist intrusion and would keep the tooth in position. As a result you will have a stable intercuspation and it would even load out distribution of supporting structures.
- Function in dynamic occlusion or movement
  - when you say movement, it is either lateral or protrusive. The function of periodontal structure would be to adapt to lateral and eccentric forces.
- How does PDL allow slight tooth movement or physiologic mobility?
- If a patient has a compromised periodontium, therefore you will have reduced support, increased risk or

increased tooth mobility which means that the tooth cannot tolerate excessive force. This can lead to trauma from occlusion, bone loss and failure of restoration.

- Main takeaway is that the periodontium is not rigid. It can adapt. It allows shock absorption, it gives sensory control and it gives functional adaptation as long as it is healthy. But if you have periodontal problem, then you will not have this function.

- Alveolar bone
- Cementum
- Gingiva

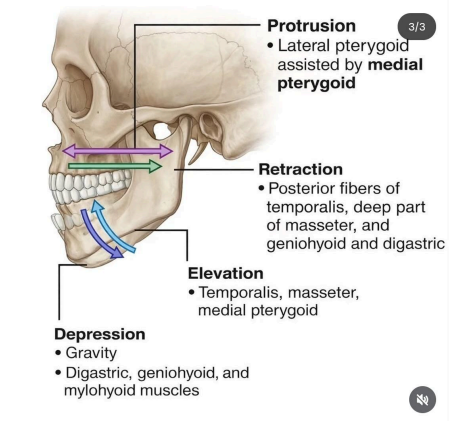


### 3. Temporomandibular joints

- Components
  - Mandibular condyle
  - Articular disc
  - Glenoid fossa
  - Articular eminence
- Role
  - It determines or gives mandibular movement.
    - In static occlusion, the position of condyles in centric relation influences the tooth contact. While in dynamic

occlusion, it controls the rotation and translation of the mandible.

- It controls the protrusive and lateral movement
  - This is in dynamic occlusion. The TMJ is actually the major determinant of occlusal pathways or movement.



### 4. Muscles of mastication

- Role
  - They provide force and movement of the mandible during function. In static occlusion, they maintain the intercuspal position. In dynamic occlusion, they control the opening and closing of the amount and the protrusion of the mandible.
- Main muscles:
  - Masseter
  - Temporalis
  - Medial pterygoid
  - Lateral pterygoid

